

PATIENT

Maya Mudriyevskaya

SPECIES

Feline

BREED

Burmese

SEX

Female

AGE

4.5 years

WEIGHT

6.8lbs

INTERPRETED BY

Maggie Machen Lamy,
DVM, DACVIM
(Cardiology)

IMAGING PERFORMED BY

Caroline Tan, DVM

HOSPITAL NAME

Silverado Vet Hospital

REFERRING VET

Dr. Marahar

INVOICE

47263

DATE

3/23/26

PRESENTING CLINICAL SIGNS

History: History of Grade 3-4 /6 murmur. Recently started on furosemide 2mg BID with significant pulmonary edema; doing better since starting furosemide is e/d no vomiting.

ECHOCARDIOGRAM FINDINGS

2D, m-mode, color flow and Doppler imaging is available. The LV wall dimensions are difficult to discern; however, the general impression of moderate hypertrophy. The LV diameter is normal with adequate function. There is a mildly hyperechoic endocardium consistent with fibrosis. The papillary muscles are mildly hypertrophied and hyperechoic. The endocardium appears remodeled. The left atrium is severely dilated with a horizontal component. No obvious thrombi. The anterior leaflet of the mitral valve is thickened and elongated, although not well visualized. No obvious stenosis. Moderate eccentric mitral regurgitation is noted. The aortic valve is normal in morphology and mobility. Aortic outflow velocities are mildly elevated on Doppler; however, this is thought to be an under-estimation. No aortic insufficiency. Normal right ventricular diameter and morphology indicating no overt evidence of pulmonary arterial hypertension. The right atrium is normal in dimension. The tricuspid valve appears normal with no tricuspid regurgitation. The pulmonic valve is normal in morphology and mobility. No pulmonic insufficiency. Normal RVOT velocity; laminar flow. Small volume pericardial effusion. No pleural effusion noted. No obvious cardiac masses.

CARDIAC CHART

FELINE CARDIAC PARAMETERS	BODY WEIGHT (kg)	HR (BPM)	IVSd (cm) <small>(Moise, Pipers)</small>	LVIDd (cm) <small>(Moise, Pipers)</small>	LVWd (cm) <small>(Moise, Pipers)</small>	FS (%)	EF (%)
NORMAL PARAMETER	-----	150-240	0.35-0.55	<2 (mean 1.5)	3.5-0.55	35-67	80-100
PATIENT	3.1	240	0.68	0.9	0.68	45	90
FELINE CARDIAC PARAMETERS	LA/AO <small>(Boon)</small>	LA/AO HEART BASE <small>(Swe) (Abbott)</small>	LA 2D short axis Base view (cm) <small>(Abbott)</small>		LVOT VEL <small>(m/s)</small>	RVOT VEL <small>(m/s)</small>	E max <small>(m/s)</small>
NORMAL	<1.5	<1.3	<1.2		<1.6	<1.3	<0.9
PATIENT	>2.0	2.2	1.6		2.0	1.8	NM

**Note: All measurements based upon multi-modal images and methods. An average value is reported.*
Adapted from June Boon, Veterinary Echocardiography, 1998
Abbott J & MacLean H JVIM 2006;20: 111-119, Moise et al. Am J Vet Res 47:1476, 1986. Pipers et al. Am J Vet Res 40:882, 1979.

INTERPRETATION OF THE FINDINGS & FURTHER RECOMMENDATIONS

The diagnosis and cause of the murmur is suspected to be mitral valve dysplasia leading to LV hypertrophy, an obstructive LVOT flow pattern and moderate MR. A primary hypertrophic component may also be contributing. The LV wall thickness may be underestimated, as image acuity is lacking. Regardless, the LA is significantly dilated indicating the patient is at high risk for



PATIENT

Maya Mudriyevskaya

SPECIES

Feline

BREED

Burmese

SEX

Female

AGE

4.5 years

WEIGHT

6.8lbs

INTERPRETED BY

Maggie Machen Lamy,
DVM, DACVIM
(Cardiology)

IMAGING PERFORMED BY

Caroline Tan, DVM

HOSPITAL NAME

Silverado Vet Hospital

REFERRING VET

Dr. Marahar

INVOICE

47263

DATE

3/23/26

decompensation and/or a thrombotic event at this time. Pericardial effusion is present, likely consistent with residual CHF.

These findings, in addition to the patient history, support CHF and continued treatment is warranted as below, including diuretic therapy. The goal is to prolong asymptomatic life; however, this patient will likely experience decline in the near future regardless. Atenolol is often used in these cases; however, given the end-stage nature, I would not utilize this in this case. Long term prognosis is poor given the age of the patient and severity of disease. Most cats can be managed on medications for an average of 8-12 months once CHF occurs.

Elective anesthesia is not advised.

Monitor for any clinical evidence of cardiac compromise, including respiratory changes and/or signs of a blood clot event (paralysis, neurologic changes, etc.).

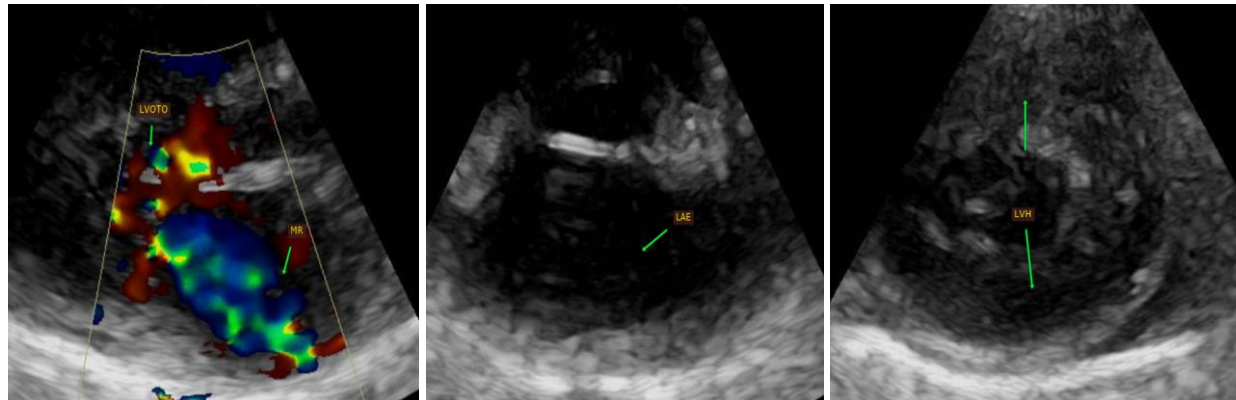
PLAN

Continue diuretic Furosemide/Lasix, increasing to 1-2mg/kg PO q12h. Institute blood thinner Clopidogrel (Plavix) 75mg tablets; give ¼ tab orally once daily (NOTE: this medication is very bitter on the cut edges. Coat in entirety).

Monitor renal values and BP in 1-2 weeks, then every 3-4 months lifelong. If doing well at that time and BP is >130mmHg, institute ACE-I (0.5mg/kg PO q12h).

Recommend recheck echocardiogram in 6 months to screen for progression, sooner if clinical

IMAGES



The information and recommendations provided are based on the images presented by the referring veterinarian. No evaluation can be communicated regarding pathology that was not visible in the image/video clips provided.

Thank you for this referral. This report was generated using transcription software, and minor dictation errors may be present. If the clinical or image interpretation does not parallel your findings or if I can be of any further assistance, please contact me.



PATIENT

Maya Mudriyevskaya

Maggie Machen Lamy, DVM

Diplomate of the American College of Veterinary Internal Medicine (Cardiology)

info@sonopath.com

SPECIES

Feline

BREED

Burmese

SEX

Female

AGE

4.5 years

WEIGHT

6.8lbs

INTERPRETED BY

Maggie Machen Lamy,
DVM, DACVIM
(Cardiology)

IMAGING PERFORMED BY

Caroline Tan, DVM

HOSPITAL NAME

Silverado Vet Hospital

REFERRING VET

Dr. Marahar

INVOICE

47263

DATE

3/23/26